



PRESENTING CLINICAL SIGNS

History: Arrhythmia. Pre-anesthetic evaluation (dental). Receives prednisolone EOD.

DATE

10/3/22

ECHOCARDIOGRAPHIC FINDINGS

2D, M-mode, and Doppler study.

PERFORMED BY:

Kelly Vazquez

INTERPRETED BY

Keith Blass, DVM,
MS, DACVIM
(Cardiology)

Left atrial size is normal. The mitral valve appears normal, though trace mitral regurgitation is present. Left ventricular wall thickness is normal. Left ventricular internal dimensions are normal. Left ventricular systolic function is mildly hyperdynamic. The aorta and aortic valve appear normal, though very mild aortic insufficiency is present. Right atrial and right ventricular dimensions are normal. The tricuspid valve appears normal, though trace tricuspid regurgitation is present. The pulmonary artery and pulmonic valve are normal. No shunting lesions are visualized. No pericardial effusion or cardiac masses are seen.

LA/Ao - 1.46
IVSd - 4.3 mm
LVPWd - 4.1 mm
LVIDd - 16.1 mm
LVIDs - 7.7 mm
FS - 52%
LVOT - 1.14 m/s
RVOT - 0.81 m/s

PATIENT

Roger Mahajan

ASSESSMENT/RECOMMENDATIONS

SPECIES

Normal echocardiogram

Feline

This examination demonstrates no evidence of structural heart disease. As such, no reason for Roger's arrhythmia is appreciated in the image set.

BREED

An ECG is recommended to further evaluate Roger's arrhythmia.

DSH

Roger's cardiovascular risk for general anesthesia is low based on this exam, however, it could be increased by the type and severity of his arrhythmia, therefore, an ECG should be performed prior to anesthesia, and precautions should be made based on the results.

SEX

No therapy is recommended based on Roger's ECG.

MN

A recheck echocardiogram is recommended if new physical exam and/or clinical abnormalities suggestive of the presence of structural heart disease develop.

AGE

13 y

WEIGHT

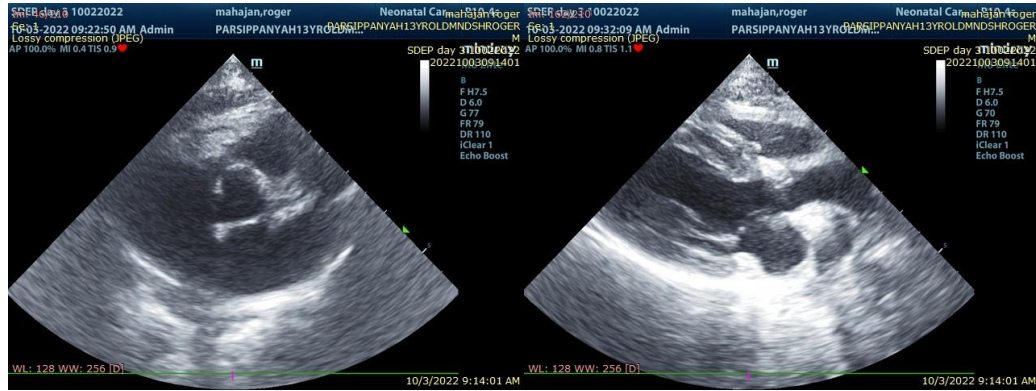
12 lb

HOSPITAL NAME

Parsippany AH

REFERRING VET

Dr. Dulude



DATE

10/3/22

PERFORMED BY:

Kelly Vazquez

INTERPRETED BY

Keith Blass, DVM,
MS, DACVIM
(Cardiology)

PATIENT

Roger Mahajan

SPECIES

Feline

BREED

DSH

SEX

MN

AGE

13 y

WEIGHT

12 lb

HOSPITAL NAME

Parsippany AH

REFERRING VET

Dr. Dulude

The information and recommendations provided are based on the images presented by the referring veterinarian. No evaluation can be communicated regarding pathology that was not visible in the image/video clips provided.

Thank you for this referral. If the clinical or image interpretation does not parallel your findings or if I can be of any further assistance please contact me.

Keith Blass, DVM, MS, DACVIM (Cardiology)
KeithBlass@gmail.com
631-804-5754